

Effect of thrombomodulin on the development of monocrotaline-induced pulmonary hypertension

Yasuharu Yamada · Junko Maruyama · Erquan Zhang · Amphone Okada · Ayumu Yokochi · Hirofumi Sawada · Yoshihide Mitani · Tatsuya Hayashi · Koji Suzuki · Kazuo Maruyama

Received: 4 March 2013 / Accepted: 13 June 2013 / Published online: 2 July 2013
© Japanese Society of Anesthesiologists 2013

Abstract

Purpose The purpose of the present study was to investigate whether thrombomodulin (TM) prevents the development of pulmonary hypertension (PH) in monocrotaline (MCT)-injected rats.

Methods Human recombinant TM (3 mg/kg/2 days) or saline were given to MCT-injected male Sprague–Dawley rats for 19 ($n = 14$) or 29 ($n = 11$) days. Control rats ($n = 6$) were run for 19 days. The mean pulmonary artery pressure (mPAP), right ventricular hypertrophy (RVH), percentages of muscularized peripheral arteries (%muscularization), and medial wall thickness of small muscular arteries (%MWT) were measured. To determine inflammatory and coagulation responses, broncho-alveolar lavage fluid (BALF) was analyzed in another set of rats ($n = 29$). Western blotting for endothelial nitric oxide synthase (eNOS) and phosphorylated eNOS (peNOS) in the lung

tissue was performed in separate rats ($n = 13$). Survival was determined in 60 rats.

Results MCT increased mPAP, RVH, %muscularization, and %MWT. TM treatment significantly reduced mPAP, %muscularization, and %MWT in peripheral arteries with an external diameter of 50–100 μm in 19 days after MCT injection, but the effect was lost after 29 days. MCT increased the levels of tumor necrosis factor alpha, monocyte chemoattractant protein-1, and thrombin-anti-thrombin complex in BALF. Expression of eNOS increased in MCT rats, while peNOS decreased. The relative amount of peNOS to total eNOS increased in MCT/TM rats compared to MCT/Vehicle rats. A Kaplan–Meier survival curve showed no difference with and without TM. **Conclusion** Although the administration of TM might slightly delay the progression of MCT-induced PH, the physiological significance for treatment is limited, since the survival rate was not improved.

Y. Yamada · J. Maruyama · E. Zhang · A. Okada · A. Yokochi · H. Sawada · K. Maruyama
Anesthesiology and Critical Care Medicine, Mie University School of Medicine, Mie, Japan

Y. Yamada · J. Maruyama (✉)
Medical Engineering, Suzuka University of Medical Science, 1001-1 Kishioka-cho, Suzuka, Mie 510-0293, Japan
e-mail: j-maru@suzuka-u.ac.jp

H. Sawada · Y. Mitani
Pediatrics, Mie University School of Medicine, Mie, Japan

T. Hayashi
Mie Prefectural College of Nursing, Mie, Japan

K. Suzuki
Pharmaceutical Sciences, Suzuka University of Medical Science, Mie, Japan

Keywords Pulmonary hypertension · Monocrotaline · Thrombomodulin · Nitric oxide

Introduction

In all conditions causing pulmonary hypertension (PH), vascular structural remodeling includes the new muscularization of normally nonmuscular pulmonary arteries and medial hypertrophy of muscular arteries, which results from vascular smooth muscle cell proliferation [1–6]. PH occurs in idiopathic pulmonary arterial hypertension (PAH); congenital heart disease with left-to-right shunt; collagen vascular disease, chronic obstructive pulmonary disease; pulmonary fibrosis, acute respiratory distress syndrome (ARDS); and persistent PH of neonate (PPHN)

[1, 7, 8]. Studies have shown the presence of inflammatory response as one of the causes of PH in patients and experimental model of PH [6], in which mononuclear cell infiltration in vascular wall and increase in pro-inflammatory cytokines such as $\text{TNF}\alpha$, IL-6, and IL-1 has been observed [9–11]. PH is a common findings in severe ARDS [12, 13], which is caused by vasoconstriction and vascular structural remodeling. This is PH associated with lung disease or hypoxemia, according to the recent clinical classification of PH [14]. ARDS is one of the presentation of multiple organ dysfunction syndrome (MODS) which is often associated with disseminated intravascular coagulation (DIC). A recombinant soluble form of thrombomodulin (TM) has been approved in Japan in 2008 for the treatment for DIC and thus the number of ARDS patients treated with TM is increasing in intensive care unit (ICU) [15]. Following these results of the clinical study in Japan, a Phase 2B trial study involving patients suffering from sepsis with DIC was undertaken in many countries in the world [16]. Subsequently, a Phase 3 trial study is currently underway in North and South America, Europe, Asia, and Australia [16].

TM is trans-membrane glycoprotein receptor for thrombin, which has anticoagulant and anti-inflammatory effects [17, 18]. TM inhibits smooth muscle cell proliferation [19]; increases endothelial nitric oxide synthase (eNOS) activity [20, 21]; reduces thrombus formation and monocyte and neutrophil chemotactic activity [22]; and inhibits pro-inflammatory cytokine production [23]. Those effects might prevent the development of vascular smooth muscle proliferation in PH, since earlier studies have shown that anti-proliferative substance such as nitric oxide (NO) [2, 24] and anti-inflammatory substance such as pyrrolidine dithiocarbamate (nuclear factor-kappaB inhibitor) ameliorate the development of PH [25–27]. Monocrotaline (MCT)-induced PH rat has been used to investigate the hypertensive pulmonary vascular structural remodeling in the inflammation-related PH [2, 3, 11, 25–28]. Therefore, we designed this study to determine if a recombinant soluble form of TM prevents the development of PH and pulmonary vascular changes in MCT-induced PH in rats.

Materials and methods

Male Sprague–Dawley rats (Clea, Japan), weighing 180–300 g were used. Each animal was randomly assigned to one of three groups: (1) rats injected with saline vehicle for 19 days after a single subcutaneous injection of saline (Saline/V, $n = 6$), (2) rats injected with saline vehicle for 19 days after a single subcutaneous injection of MCT (60 mg/kg) (MCT/V, $n = 6$), (3) rats injected with human

recombinant TM (3 mg/kg) (Asahi Kasei, Co., Japan) for 19 days after a single subcutaneous injection of MCT (MCT/TM, $n = 8$). The animals were subcutaneously injected with TM once every 2 days at a dose of 3 mg/kg of TM dissolved in saline. Subcutaneous administrations of TM were begun from 1 day before the injection of MCT and continued for 19 days, finishing on the morning of the 19th day after the injection of MCT. Food and water were provided ad libitum. Another set of rats with TM for 29 days after a single subcutaneous injection of MCT (MCT/TM29, $n = 6$) and rats injected with saline vehicle for 29 days after a single subcutaneous injection of MCT (MCT/V29, $n = 5$) were also used. To save the number of rats, control rats for 29-day study (rats injected with saline vehicle for 29 days after a single subcutaneous injection of saline) were not run, basically similar to control rats for 19-day study. We also evaluated the effect of TM on survival by way of subcutaneous injection of TM at a dose of 3 mg/kg every 2 days to rats until the time of death in the MCT/TM group.

Pulmonary artery pressure

Seventeen days after the injection of MCT, blood pressure was measured in the rats using the tail cuff method (BP-98A, Softron, Japan). Rats were anesthetized with pentobarbital sodium (45 mg/kg) administered intraperitoneally. A pulmonary artery catheter (Silastic tubing, 0.31 mm ID and 0.64 mm OD) was inserted via the right external jugular vein into the pulmonary artery using a closed-chest technique, as previously described [2–5]. Forty-eight hours after catheterization (19 days after the injection of MCT), with the rat fully conscious, allowing sufficient time for recovery from the effect of anesthesia, the mean pulmonary artery pressure (PAP) was recorded with a physiological transducer and an amplifier system (AP 620G, Nihon Kohden, Japan) once the rats were calm.

Structural studies

Preparation of lung tissue for morphometric analysis

A lung section for morphometric analysis of the vasculature was prepared using the barium injection method that has been reported in detail [2–5]. Sections were stained for elastin by the Van Gieson method. The right ventricle (RV) of the heart was dissected from the left ventricle plus septum (LV + S) and weighed separately. The heart weight ratio (RV/LV + S) was calculated to assess RVH.

Morphometric analysis of pulmonary arteries

Light microscope slides were analyzed, without previous knowledge of the treatment groups. All barium-filled arteries

in each tissue section were examined at $\times 400$. Each artery was identified as being one of three structural types for the presence of muscularity: fully muscularized (with a complete medial coat muscle), partially muscularized (incomplete medial coat, or only a crescent of muscle being present), and nonmuscular (no muscle apparent) [2–5]. The percentages of combined fully and partially muscularized arteries in peripheral pulmonary arteries with an external diameter between 15 and 50 μm and between 50 and 100 μm were calculated. For fully muscular arteries between 51 and 100 μm in diameter (an average of 10 arteries were found per section), the wall thickness of the media (distance between external and internal elastic laminae) was measured along the shortest curvature, and the percent medial wall thickness (%MWT) was calculated [2–5].

BALF sampling

In the other sets of rats ($n = 29$), BAL was performed 19 days after injection of MCT. The rats were anesthetized by the intraperitoneal administration of pentobarbital. Blood samples were collected by puncturing the inferior vena cava and were placed in tubes containing 1:10 volume of 3.8 % sodium citrate. BALF was obtained by cannulating the trachea with polyethylene tube and by infusing the lungs with 3-ml aliquots of sterile 0.9 % saline. The recovered fluid was centrifuged ($1,000 \times g$, 5 min, 4 $^{\circ}\text{C}$), and the cell-free supernatant was stored immediately at -80°C until use for biochemical analysis. The total number of cells in the BALF was measured using a nucleocounter from ChemoMetec (Allerd, Denmark). For cell differential counting, the BALF was centrifuged using a cytofuge (Medite, Germany), and the cells were stained with MayGrunwald–Giemsa (Merck, Darmstadt, Germany).

Biochemical analysis

Biochemical analysis was performed using a commercial kit according to the manufacturer's instructions: total protein, BCATM protein assay kit (Pierce, Rockford, IL, USA); TNF α and monocyte chemoattractant protein-1(MCP-1), EIA kits from BD Biosciences Pharmingen (San Diego, CA, USA); Thrombin activity and TAT complex, enzyme immunoassay kits from Cedarlane Laboratories (Hornly, ON, Canada).

Measurement of plasma TM

To determine the effectiveness of TM supplementation once every 2 days, we determined the plasma TM level in rats ($n = 4$). Blood samples were obtained 3, 9, 24, 38, and 48 h after the subcutaneous injection of TM (3 mg/kg). The TM levels were determined by high-performance

liquid chromatography (LC-10A, Shimazu, Japan). The detection limit was 0.5 FU/ml TM.

Western blotting for eNOS and peNOS

In another set of experiments with 13 rats, Western blotting for eNOS and peNOS in whole lung tissue was performed in MCT-injected rats with and without TM for 19 days. After sacrificing by decapitation and exsanguination under pentobarbital anesthesia, lung specimens were obtained. Samples were homogenized and centrifuged, and the supernatant was subjected to SDS-PAGE on 10 % acrylamide gels and blotted onto a PVDF membrane. Blots were incubated with a mouse monoclonal antibody raised against mouse eNOS (BD Transduction Laboratories G10296, lot 21527, 1:2,500 dilution) and rabbit peNOS (Cell signaling phosho-eNOS, ser-1177 #9751, 1:2,400 dilution) primary antibody and a secondary antibody (Amersham NA 931, 1: 20,000 dilution) were used. In addition to samples, molecular weight standards, eNOS standards (mouse macrophage; Transduction Laboratories), and beta actin (SIGMA A 5441, 1:200,000 dilution) were run at the same time.

Data analysis

Values are expressed as mean \pm SE. One-way analysis of variance was used to compare the effects of MCT and TM in the three groups. When significant variance was found, Scheffe's test was used to establish which groups were different. In the 29-day study, Student's *t* test was used. Differences were considered significant at $P < 0.05$.

Results

Rats 19 days after monocrotaline injection

Mean pulmonary artery pressure and RVH (Fig. 1)

The mean PAP of the Saline/Vehicle group was 18.0 ± 1.0 mmHg. The MCT/V group had a significantly higher mean PAP than the Saline/Vehicle group (Fig. 1). There were significant differences between MCT/V and MCT/TM rats (32.3 ± 2.0 vs. 27.3 ± 1.0 mmHg, respectively). MCT caused significant RVH (Fig. 1). TM had no effect on the development of RVH (Fig. 1). There were no differences in the mean systemic artery pressure among the groups.

Vascular structural changes (Fig. 2)

In rats 19 days after the injection of MCT, MCT significantly increased the percentages of combined fully and

Fig. 1 *Top left I*: Mean pulmonary artery pressure, *Top right II*: Mean artery pressure, *bottom left III*: RV/LV + S. *Saline/V* rats injected with saline vehicle for 19 days after a single subcutaneous injection of saline, *MCT/V* rats injected with saline vehicle for 19 days after a single subcutaneous injection of monocrotaline, *MCT/TM* rats injected human recombinant TM (Asahi Kasei, Co. Japan) for 19 days after a single subcutaneous injection of monocrotaline. *NS* not significant. Values are mean ± SE

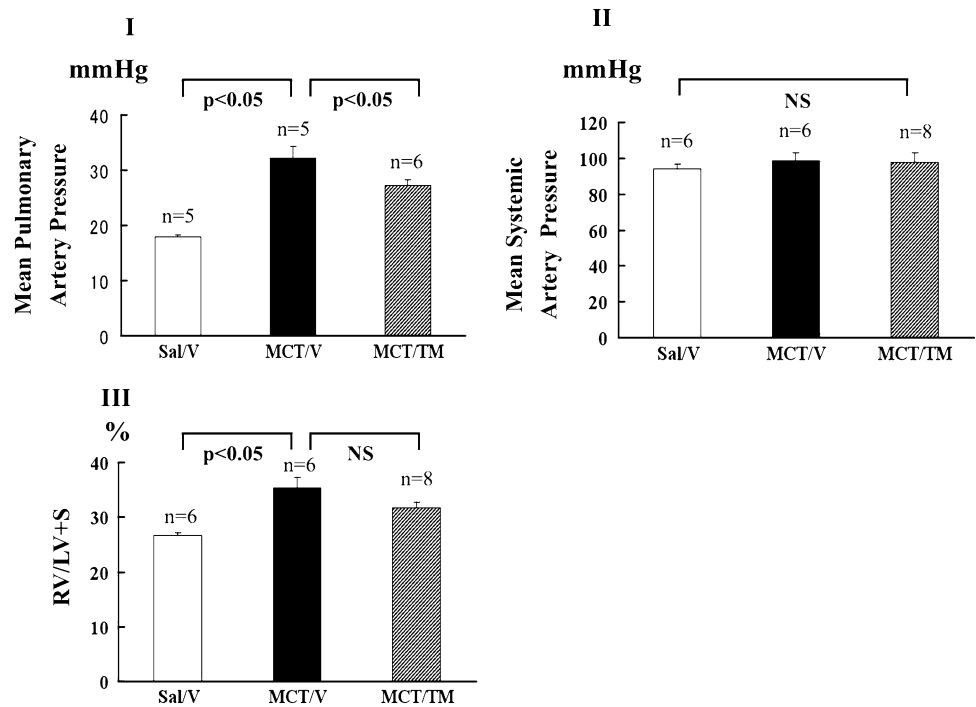
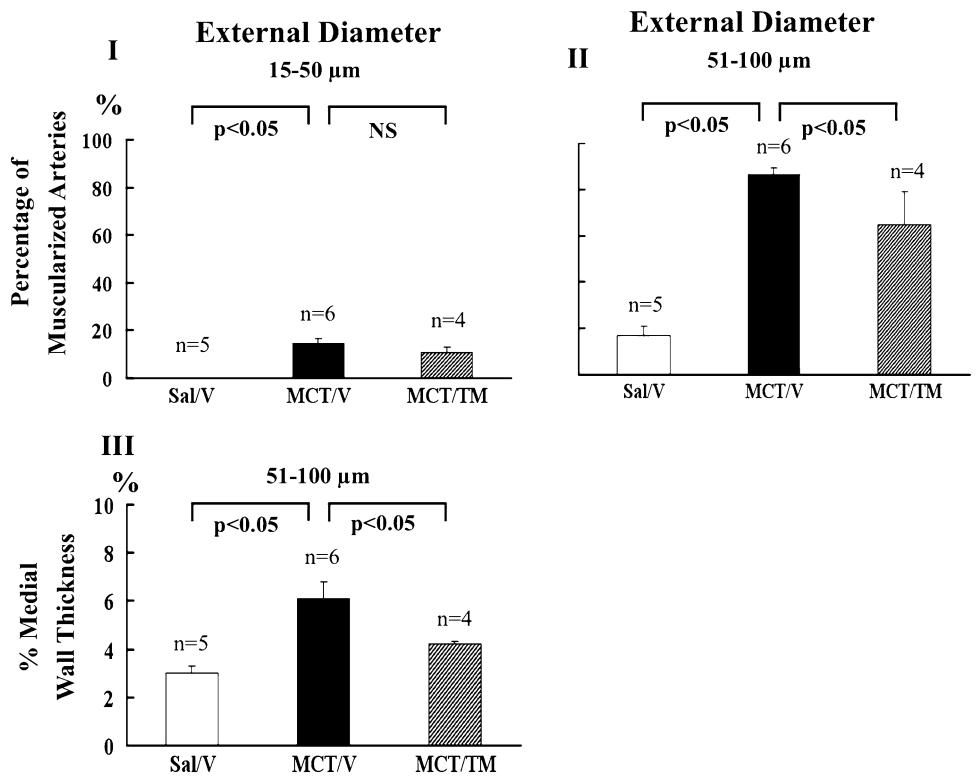


Fig. 2 Vascular structural changes 19 days after monocrotaline injection with and without thrombomodulin treatment. *Top left I*: % muscularization of peripheral pulmonary arteries with an external diameter between 15 and 50 μm, *top right II*: % muscularization of peripheral pulmonary arteries with an external diameter between 51 and 100 μm, *bottom left III*: % MWT of small muscular arteries with an external diameter between 51 and 100 μm. *Saline/V*— normal control rats with saline, *MCT/V* monocrotaline-injected rats without thrombomodulin, *MCT/TM*+ monocrotaline-injected rats with thrombomodulin. *NS* not significant. Values are mean ± SE



partially muscularized arteries in peripheral pulmonary arteries from 0.1 ± 0.1 to 14.9 ± 1.6 % ($P < 0.05$) in those with external diameters between 15 and 50 μm and from 9.8 ± 2.8 to 83.6 ± 1.5 % ($P < 0.05$) in those with external diameters between 51 and 100 μm (Fig. 2). TM significantly reduced this increase in external diameter

between 51 and 100 μm to 64.7 ± 14.4 %, but not in those between 15 and 50 μm. MCT significantly increased %MWT from 3.02 ± 0.28 to 6.14 ± 0.71 % in the fully muscular arteries between 51 and 100 μm in external diameter ($P < 0.05$), in which TM significantly reduced this increase to 4.16 ± 0.03 % ($P < 0.05$).

Rats 29 days after monocrotaline injection

In rats 29 days after the injection of MCT, TM did not significantly affect the percentages of combined fully and partially muscularized arteries at 15–50 μm of external diameter in peripheral pulmonary arteries ($52.3 \pm 11.1\%$ in MCT/V29 group vs. $49.6 \pm 7.2\%$ in MCT/TM29 group; $P = 0.8517$), or at 51–100 μm of external diameter in peripheral pulmonary arteries ($100.0 \pm 0\%$ both in MCT/V29 and MCT/TM29 group). TM did not also affect %MWT of fully muscularized arteries between 51 and 100 μm in external diameter in rats ($7.6 \pm 0.6\%$ in MCT/V29 group vs. $7.8 \pm 0.2\%$ in MCT/TM29 group; $P = 0.7626$).

Effect of TM on survival (Fig. 3)

A Kaplan–Meier survival curve showed no difference in survival between rats with and without TM.

Plasma TM concentration (Fig. 4)

The TM concentration was 0.65 FU/ml ($n = 2$) in Vehicle rats, which was elevated to 2011.3 ± 409.3 FU/ml ($n = 4$) after 9 h, and remained elevated during 48 h after subcutaneous injection.

Inflammation and cytokine levels

Monocrotaline increased total protein levels (211.93 ± 13.35 $\mu\text{g/ml}$ in Sal/V group vs. 554.04 ± 11.59 $\mu\text{g/ml}$ in MCT/V group; $P < 0.05$) in the BALF reflecting the degree of MCT-induced lung injury. Treatment with TM did not affect these increases (599.62 ± 97.15 $\mu\text{g/ml}$ in MCT/TM group vs. MCT/V group; $P = 0.7770$). The neutrophil population was increased in MCT rats ($0.073 \pm 0.026 \times 10^{-5}/\text{ml}$ in Sal/V group vs. $1.408 \pm 0.3 \times 10^{-5}/\text{ml}$ in MCT/V

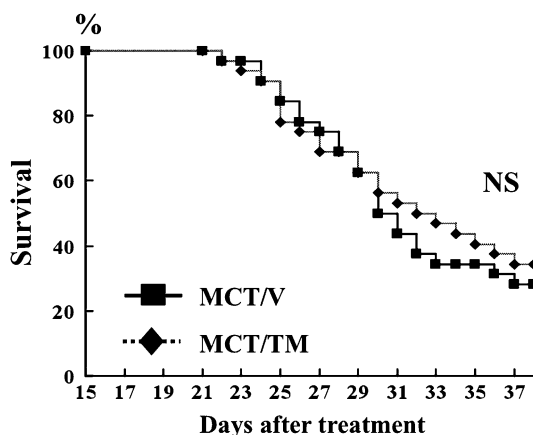


Fig. 3 A Kaplan–Meier survival curve of rats with and without thrombomodulin treatment

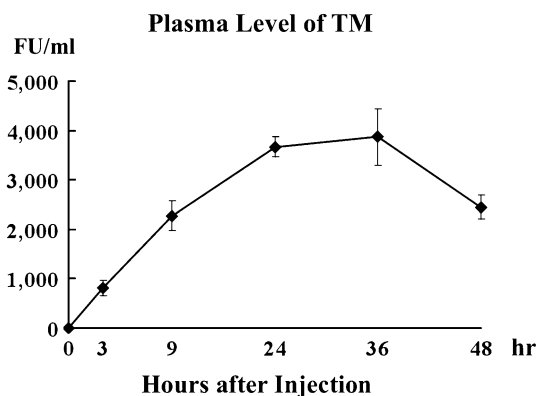


Fig. 4 Changes in the plasma TM level after the single injection of human recombinant thrombomodulin

group; $P < 0.05$). These models were also associated with a significant increase in the proinflammatory cytokines, $\text{TNF}\alpha$ (36.14 ± 2.39 pg/ml in Sal/V group vs. 50.03 ± 4.45 pg/ml in MCT/V group; $P < 0.05$) and MCP-1 (31.0 ± 25.0 pg/ml in Sal/V group vs. 695 ± 179 pg/ml in MCT/V group; $P < 0.05$). Treatment with TM did not affect the increases of neutrophil population ($1.42 \pm 0.36 \times 10^{-5}/\text{ml}$ in MCT/TM group vs. MCT/V group; $P = 0.8847$), $\text{TNF}\alpha$ (46.21 ± 2.60 pg/ml in MCT/TM group vs. MCT/V group; $P = 0.7063$), or MCP-1 (713 ± 198 pg/ml in MCT/TM group vs. MCT/V group; $P = 0.9965$).

Procoagulant markers (Fig. 5)

Monocrotaline injected rats exhibited increased thrombin activity in BALF (4093 ± 61 u/l in Sal/V group vs. 5713 ± 262 u/l in MCT/V group; $P < 0.05$). Treatment with TM did not change thrombin activity (5366 ± 66 u/l in MCT/TM group vs. MCT/V group; $P = 0.992$). The concentration of thrombin-antithrombin III (TAT) complex in the BALF and plasma were significantly increased in MCT rats. In plasma, TM reduced the TAT level, although the difference was non-significant. In BALF, TM increased the TAT level compared to non-treated rats.

Western blotting for eNOS and peNOS (Fig. 6)

eNOS expression was increased in MCT/V rats compared to SAL/V rats, which returned to SAL/V levels in MCT/TM rats. peNOS expression was decreased in both MCT/V and MCT/TM rats compared to SAL/V rats. These results suggested that the relative amount of peNOS to total eNOS was increased in MCT/TM rats compared to MCT/V rats, although the difference was not statistically significant (0.19 ± 0.04 in MCT/TM group vs. 0.12 ± 0.01 in MCT/V group; $P = 0.190$).

Fig. 5 TAT complex in BALF (left) and in plasma (right). Saline/V normal rats, MCT/V monocrotaline-injected rats without TM, MCT/TM monocrotaline-injected rats with TM. NS not significant. Values are mean ± SE

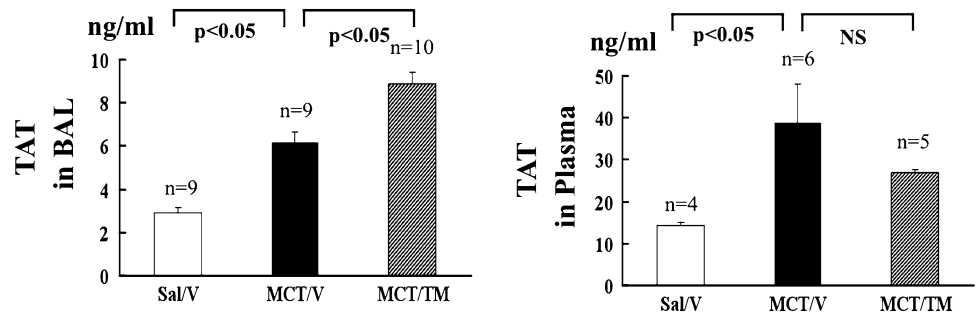
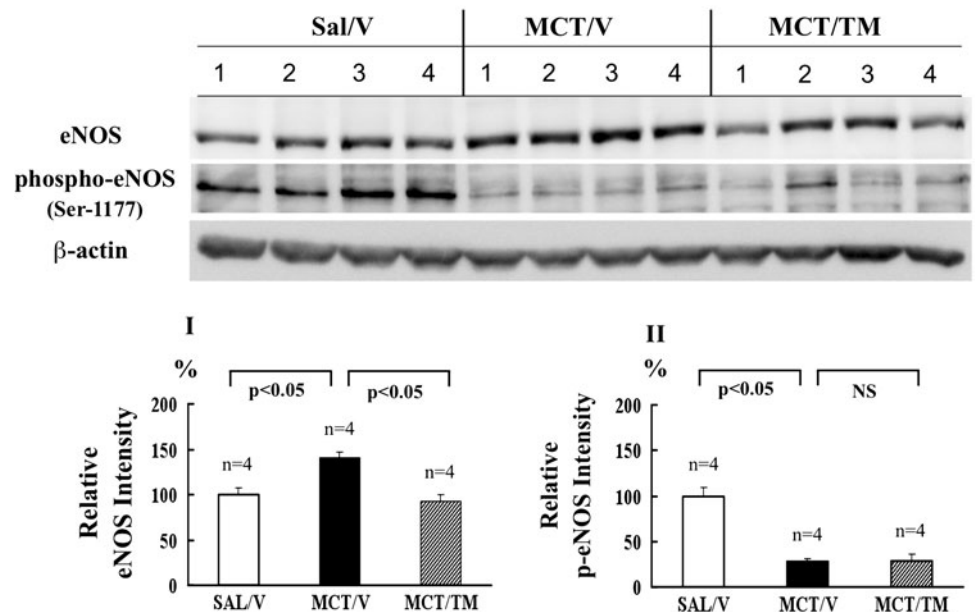


Fig. 6 Western blotting for eNOS (left) and peNOS (right) Saline/V normal rats, MCT/V monocrotaline-injected rats without TM, MCT/TM monocrotaline-injected rats with TM. NS not significant. Values are mean ± SE. n number of rats



Discussion

Monocrotaline induced the new muscularization of peripheral pulmonary arteries, medial hypertrophy of muscular arteries, rise in PAP, and RVH. TM treatment partly but significantly reduced the vascular changes and PAP after 19 days of MCT injection. But the improvement was cancelled after 29 days of MCT injection, resulting in no improvement of the survival rate.

TM levels could be achieved at least for 2 days with one dose of 3 mg/kg of recombinant human soluble TM. This dose is higher than that administered to humans undergoing therapy for DIC [15]. The TM level for the prevention of thrombus formation in humans was maintained for at least 6 days after single sc injection of the same drug at doses of 0.30 and 0.45 mg/kg [29]. The dose regimen in our study (3 mg/kg/2 days) was similar to the studies of TM administration in experimental glomerulonephritis (3 mg/kg/day) [22] and sepsis (1 mg/kg/day) [23] in rats.

At 19 days of MCT injection, eNOS expression was upregulated. This result is different from earlier studies in which expression of eNOS mRNA is reduced in lungs of

MCT-induced PH rats at 90 days of monocrotaline injection [26]. Combined with these and present studies, we speculate that eNOS expression might be upregulated in an early phase of MCT-induced PH, and be downregulated in late phase [26]. Because TM increases peNOS in cultured human umbilical endothelial cells [20, 21], we expected to detect the upregulation of peNOS due to TM in MCT-injected rats. Although we could not detect this upregulation, relative amount of peNOS compared to eNOS seemed to be increased with TM. Total eNOS level was increase in MCT/V rats but peNOS levels were similar between MCT/V and MCT/TM rats. peNOS is active form of eNOS, thus ratio of active eNOS (peNOS) to total eNOS seemed to be increased in MCT/TM rats. This might explain in part the slight reduction of mPAP and vascular changes in 19 day study. Long term NO inhalation and administration of NO-precursor, L arginine, ameliorated the development of experimental PH in rats [2, 24].

Plasma TM levels are decreased in patients with pulmonary arterial hypertension [30, 31]. The decrease in TM might contribute the progression of in situ thromboses [27], one of the pathological abnormalities of PH. TM production

seemed to decrease with disease progression in MCT-induced PH, because mRNA and Western blot analysis of the lung have shown a decrease in expression 14, 21, and 28 days after the injection of monocrotaline [28]. We speculated that the administration of TM might be a supplementation therapy, but TM administration did not ameliorate the development of PH in the present study. Although exogenous TM failed to prevent the occurrence of PH in the present study, treatment to increase the endogenous production of TM in endothelial cells might reduce the severity of PH. Continuous prostacyclin therapy, which improves clinical symptoms and survival in patients with PPH, increased TM production by endothelial cells [31]. Prostacyclin has a pivotal role as a vasorelaxant as well as an inhibitor of platelet aggregation, along with anti-inflammatory and anti-proliferative properties [32]. This additional effect might be important for improvement of prognosis for PH.

In our model, the development of PH was associated with the inflammatory response, as shown by the increase in the level of TNF α , the neutrophil cell count, and concentration of total protein in BALF in MCT rats. This confirmed the inflammatory aspect in the pathogenesis of PH [6]. MCP-1 was also increased in MCT rats, which might be induced by TNF α since, in an in vitro study, MCP-1 was induced by TNF α [33]. MCP-1 is a potent monocyte attractant, initiating cellular migration and activation and recruiting inflammatory cells, which might explain the increase in neutrophil counts in BALF in MCT rats. Since blockade of the MCP-1 signal pathway prevented the development of PH [25, 34], an increase in MCP-1 might be one of the causes of PH. Although peptide derived from human TM reduced MCP-1 in uveitis [35], this might not be the case in this study of PH since TM did not prevent the increase in MCP-1 in BALF.

Activation of the coagulation system was shown in MCT rats as measured by the increased level of TAT. Hypercoagulability is involved in the pathogenesis of PH [6]. The anticoagulant effect of human recombinant TM in BALF might not be relevant in our model of PH, while this effect was observed in plasma, as shown by the trend of the decrease in TAT, suggesting that the effect of TM in the blood is anticoagulation. The mechanism by which TAT in BALF increased in TM-treated rats is unclear. In a previous study, protein C inhibition protected against the development of MCT-induced PH in mice [36], suggesting that activated protein C probably does not prevent the development of MCT-induced PH. This might explain why TM failed to prevent the development of MCT-induced PH in the present study, because the thrombin-thrombomodulin complex activates protein C [17, 37].

In summary, TM partially prevented the development of PH at some point during the course in the present study.

However, a therapeutic role in preventing the development of PH is limited because the vascular changes in TM-treated rats finally caught up with those in non-TM-treated rats, and TM did not improve survival.

Acknowledgments This work was supported in part by Grants-In-Aid for Scientific Research 16390449, 20590920, and 21592003 from the Japanese Ministry of Education, Science and Culture.

References

1. Rabinovitch M. Molecular pathogenesis of pulmonary arterial hypertension. *J Clin Invest*. 2008;118:2372–9.
2. Mitani Y, Maruyama K, Sakurai M. Prolonged administration of L-arginine ameliorates chronic pulmonary hypertension and pulmonary vascular remodeling in rats. *Circulation*. 1997;96:689–769.
3. Maruyama J, Maruyama K, Mitani Y, Kitabatake M, Yamauchi T, Miyasaka K. Continuous low-dose NO inhalation does not prevent monocrotaline-induced pulmonary hypertension in rats. *Am J Physiol*. 1997;272:H517–24.
4. Zhang E, Jiang B, Yokochi A, Maruyama J, Mitani Y, Ma N, Maruyama K. Effect of all-trans-retinoic acid on the development of chronic hypoxia-induced pulmonary hypertension. *Circ J*. 2010;74:1696–703.
5. Jiang BH, Maruyama J, Yokochi A, Iwasaki M, Amano H, Mitani Y, Maruyama K. Prolonged nitric oxide inhalation fails to regress hypoxic vascular remodeling in rat lung. *Chest*. 2004;125:2247–52.
6. Dorfmueller P, Perros F, Balabanian K, Humbert M. Inflammation in pulmonary arterial hypertension. *Eur Respir J*. 2003;22:358–63.
7. Maruyama K, Maruyama J, Utsunomiya H, Furuhashi K, Kurobuchi M, Katayama Y, Yada I, Muneyuki M. Effect of nicardipine on pulmonary hypertension after repair of congenital heart defects in early postoperative period. *J Anesth*. 1993;7:95–101.
8. Maruyama K, Nakai Y, Chikusa H, Muneyuki M. Verapamil reduced pulmonary hypertension in adult respiratory distress syndrome. *J Anesth*. 1994;8:480–1.
9. Fujita M, Shannon JM, Irvin CG, Fagan KA, Cool C, Augustin A, Mason RJ. Overexpression of tumor necrosis factor- α produces an increase in lung volume and pulmonary hypertension. *Am J Physiol Lung Cell Mol Physiol*. 2001;280:L39–49.
10. Miyata M, Ito M, Sasajima T, Ohira H, Kasukawa R. Effect of a serotonin receptor antagonist on interleukin-6-induced pulmonary hypertension in rats. *Chest*. 2001;119:554–61.
11. Stenmark KR, Morganroth ML, Remigio LK, Voelkel NF, Murphy RC, Henson PM, Mathias MM, Reeves JT. Alveolar inflammation and arachidonate metabolism in monocrotaline-induced pulmonary hypertension. *Am J Physiol*. 1985;248:H856–66.
12. Zapol WM, Jones R. Vascular components of ARDS. Clinical pulmonary hemodynamics and morphology. *Am Rev Respir Dis*. 1987;136:471–4.
13. Snow RL, Davies P, Pontoppidan H, Zapol WM, Reid L. Pulmonary vascular remodeling in adult respiratory distress syndrome. *Am Rev Respir Dis*. 1982;126:887–92.
14. Simonneau G, Robbins IM, Beghetti M, Channick RN, Delcroix M, Denton CP, Elliott CG, Gaine SP, Gladwin MT, Jing ZC, Krowka MJ, Langleben D, Nakanishi N, Souza R. Updated clinical classification of pulmonary hypertension. *J Am Coll Cardiol*. 2009;54:S43–54.

15. Saito H, Maruyama S, Shimazaki S, Yamamoto Y, Aikawa N, Ohno R, Hirayama A, Matsuda T, Asakura H, Nakashima M, Aoki N. Efficacy and safety of recombinant human soluble thrombomodulin (ART-123) in disseminated intravascular coagulation: results of a phase III, randomized, double-blinded clinical trial. *J Thromb Haemost.* 2007;5:31–41.
16. Iba T, Nagaoka I, Boulat M. The anticoagulant therapy for sepsis-associated disseminated intravascular coagulation. *Thromb Res.* 2013 in press.
17. Weiler H, Isermann BH. Thrombomodulin. *J Thromb Haemost.* 2003;1:1515–24.
18. Van de Wouwer M, Conway EM. Novel functions of thrombomodulin in inflammation. *Crit Care Med.* 2004;32:S254–61.
19. Grinnell BW, Berg DT. Surface thrombomodulin modulates thrombin receptor responses on vascular smooth muscle cell. *Am J Physiol.* 1996;270:H603–9.
20. Shi CS, Shi GY, Chang YS, Han HS, Kuo CH, Liu C, Huang HC, Chang YJ, Chen PS, Wu HL. Evidence of human thrombomodulin domain as a novel angiogenic factor. *Circulation.* 2005;111:1627–36.
21. David-Duflho M, Brussel EMV, Topal G, Walch L, Brunet A, Rendu F. Endothelial thrombomodulin induces Ca^{2+} signals and nitric oxide synthesis through epidermal growth factor receptor kinase and calmodulin kinase II. *J Biol Chem.* 2005;280:35999–6006.
22. Ikeguchi H, Maruyama S, Morita Y, Fujita Y, Kato T, Natori Y, Akastu H, Campbell W, Okada N, Okada H, Yuzawa Y, Mastuo S. Effects of human soluble thrombomodulin on experimental glomerulonephritis. *Kid Int.* 2002;61:490–501.
23. Nagato M, Okamoto K, Abe Y, Higure A, Yamaguchi K. Recombinant human soluble thrombomodulin decreases the plasma high-mobility group box-a protein levels, whereas improving the acute liver injury and survival rates in experimental endotoxemia. *Crit Care Med.* 2009;37:2181–6.
24. Roberts JD Jr, Roberts CT, Jones RC, Zapol WM, Bloch KD. Continuous nitric oxide inhalation reduces pulmonary arterial structural changes, right ventricular hypertrophy, and growth retardation in the hypoxic newborn rat. *Circ Res.* 1995;76:215–22.
25. Kimura H, Kasahara Y, Kurosu K, Sugito K, Takiguchi Y, Terai M, Mikata A, Natsume M, Mukaida N, Matsushima K, Kuriyama T. Alleviation of monocrotaline-induced pulmonary hypertension by antibodies to monocyte chemoattractant and activating factor/monocyte chemoattractant protein-1. *Lab Invest.* 1998;78:571–81.
26. Chang LT, Sun CK, Sheu JJ, Chiang CH, Youssef AA, Lee FY, Wu CJ, Yip HK. Cilostazol therapy attenuates monocrotaline-induced pulmonary arterial hypertension in rat model. *Circ J.* 2008;72:825–31.
27. Sawada H, Mitani Y, Maruyama J, Jiang BH, Ikeyama Y, Dida FA, Yamamoto H, Imanaka-Yoshida K, Shimpo H, Mizoguchi A, Maruyama K, Komada Y. A nuclear factor-kappaB inhibitor pyrrolidine dithiocarbamate ameliorates pulmonary hypertension in rats. *Chest.* 2007;132:1265–74.
28. Wang FM, Wang DW, Yang SW. Changes of thrombomodulin in rats with pulmonary hypertension induced by monocrotaline. *Zhonghua Er Ke Za Zhi.* 2007;45:297–8.
29. Moll S, Lindley C, Pescatore S, Morrison D, Tsuruta K, Mohri M, Serada M, Sata M, Shimizu H, Yamada K, White GC II. Phase I study of a novel recombinant human soluble thrombomodulin, ART-123. *J Thromb Haemost.* 2004;2:1745–51.
30. Cacoub P, Karmochkine M, Dorent R, Nataf P, Piette JC, Godeau P, Gandjbakhch IG, Boffa MC. Plasma levels of thrombomodulin in pulmonary hypertension. *Am J Med.* 1996;101:160–4.
31. Sakamaki F, Kyotani S, Nagaya N, Sato N, Oya H, Satoh T, Nakanishi N. Increased plasma p-selectin and decreased thrombomodulin in pulmonary arterial hypertension were improved by continuous prostacyclin therapy. *Circulation.* 2000;102:2720–5.
32. Ventetuolo CE, Klinger JR. WHO Group I pulmonary arterial hypertension: current and investigative therapies. *Prog Cardiovasc Dis.* 2012;55:89–103.
33. Strieter RM, Kunkel SL. The immunopathology of chemotactic cytokines. *Adv Exp Med Biol.* 1993;351:19–28.
34. Ikeda Y, Yonemitsu Y, Kataoka C, Kitamoto S, Yamaoka T, Nishida K, Takeshita A, Egashira K, Sueishi K. Anti-monocyte chemoattractant protein-1 gene therapy attenuates pulmonary hypertension in rats. *Am J Physiol Heart Circ Physiol.* 2002;283:H2021–8.
35. Jin H, Yang X, Liu K, Gu Q, Xu X. Effects of a novel peptide derived from human thrombomodulin on endotoxin-induced uveitis in vitro and in vivo. *FEBS Lett.* 2011;585:3457–64.
36. Nishii Y, Gabazza EC, Fujimoto H, Nakahara H, Takagi T, Bruno N, D'Alessandro-Gabazza CN, Maruyama J, Maruyama K, Hayashi T, Adachi Y, Suzuki K, Taguchi O. Protective role of protein C inhibitor in monocrotaline-induced pulmonary hypertension. *J Thromb Haemost.* 2006;4:2331–9.
37. Suzuki K, Kusumoto H, Deyashiki Y, Nishioka J, Maruyama I, Zushi M, Kawahara S, Honda G, Yamamoto S, Horiguchi S. Structure and expression of human thrombomodulin, a thrombin receptor on endothelium acting as a cofactor for protein C activation. *EMBO J.* 1987;6:1891–7.